

Strahlenther Onkol 2014
DOI 10.1007/s00066-014-0668-3
Received: 11 February 2014
Accepted: 31 March 2014

© Springer-Verlag Berlin Heidelberg 2014

Ming-Hui Mao · Jian-Guo Zhang · Jie Zhang · Lei Zheng · Shu-Ming Liu ·
Ming-Wei Huang · Yan Shi

Department of Oral and Maxillofacial Surgery, Peking University
School and Hospital of Stomatology, Beijing, P.R.China

Postoperative [¹²⁵I] seed brachytherapy in the treatment of acinic cell carcinoma of the parotid gland

With associated risk factors

Acinic cell carcinoma (ACC) was initially thought to be a benign entity. In the early 1950s, however, upon recognizing its ability to metastasize and recur locally, Foote and Buxton became the first to label it a carcinoma [1]. ACC is now known to represent the third most common epithelial malignancy of the salivary glands in adults, after mucoepidermoid carcinoma and adenoid cystic carcinoma.

Traditionally, surgery has been the mainstay of clinical management. Wide surgical excision of the neoplasia, including total or superficial parotidectomy, is generally recommended to prevent recurrence. Additional measures may include sacrifice of the facial nerve in patients with deep lobe invasion and facial nerve involvement, present more often with advanced tumor stage, which unfortunately seriously affects the quality of life of patients [2, 3].

The role of radiotherapy in acinic cell salivary tumors remains controversial, since ACC has generally not been regarded as being very radiosensitive. Nevertheless, there appears to be a role for adjuvant postoperative radiotherapy in the treatment of ACC. Studies have shown a good response to postoperative radiotherapy, especially for cases with risk factors such as residual or recurrent tumor, invasion of the facial nerve in the parotid gland, positive resection margins, advanced tumor stage, or tumor spillage [4, 5]. However,

many radiotherapeutic techniques come with significant drawbacks. For instance, external beam radiotherapy (EBRT) of the head and neck region is associated with some severe short- and long-term complications, such as extensive oral mucosal ulceration, osteoradionecrosis of the upper or lower jaw, xerostomia, dermatitis, and sometimes hearing loss [6–9]. Fast neutron radiotherapy has also exhibited good efficacy for the treatment of some residual tumors, but its disadvantages include high costs and grade 3/4 side effects [10].

Brachytherapy can be used to deliver a high dose of radiation, which diminishes sharply with increasing distance, to a limited volume, thereby minimizing the risk of damage to surrounding normal tissues [11], adjacent vital structures, and clinical staff. These properties make it an ideal technique for postoperative radiotherapy for ACC. For this study, cases of ACC patients with risk factors treated postoperatively with iodine-125 (¹²⁵I) seed brachytherapy were reviewed, and the effectiveness of the therapy, its complications, and the relevant prognostic factors were evaluated.

Patients and methods

From January 2004 to February 2012, 29 patients (12 females and 17 males; age range, 13–73 years; median age, 37.3 years) with ACC of the parotid gland were

treated at Peking University School and the Hospital of Stomatology. Treatment was approved in all cases by the ethics committee of Peking University School and the Hospital of Stomatology, in accordance with the Helsinki Declaration of 1975, and all patients provided written informed consent before their inclusion in the study. Patient characteristics are shown in **Table 1**. For this retrospective study analysis, patients were divided into two groups: recurrent cases and initial cases. Of the five recurrent cases, four involved the parotid gland and one involved the infratemporal fossa. There were 12 recurrence events (range, 1–5; median, 2.4) among the five cases. The remaining 24 initial presentation cases involved the parotid gland. Cases were staged according to the 2010 UICC staging system for malignant tumors of major salivary glands.

All patients underwent surgery as the first treatment. Of initial cases involving the parotid gland, 17 patients had invasion of the facial nerve with partial residual tumor, five patients had positive tumor margins for advanced stage disease, and two patients had tumor spillage. Of the recurrent cases, none of the patients had a clear boundary for the scar from the operation or radiotherapy, leading to difficulty in extended resection. All patients were diagnosed as having ACC based on histopathologic examination, and they all

Table 1 Patient characteristics

Characteristic	Value
Age (years)	
Median	37.3
Range	13–73
Gender (n)	
Male	12 (41.3%)
Female	17 (58.7%)
Tumor site (n)	
Parotid	28 (97%)
Infratemporal fossa	1 (3%)
Recurrent tumor (n)	5 (17.2%)
Tumor size (cm)	1.5–4
Mean (cm)	2.5
Initial T stage (n)	24 (82.8%)
T1	6 (20.7%)
T2	14 (48.2)
T3	3 (10.3%)
T4	1 (3.4%)
Risk factor (n)	
Invaded facial nerve	17 (58.6%)
Advanced stage with positive margins	5 (17.2%)
Tumor spillage	2 (6.9%)
Recurrent tumor	5 (17.2%)
Histology (n)	
Grade 1	12 (41.4%)
Grade 2	15 (51.7)
Grade 3	2 (6.9%)
Interval between operation and brachytherapy (weeks)	
< 2 weeks	18 (62.1%)
2–4 weeks	4 (13.8%)
> 4 weeks	7 (24.1%)
Previous external beam radiotherapy (n)	
Yes	2 (6.7%)
No	27 (93.3%)
Cumulative dose of external beam radiotherapy (n)	
60 Gy	2
> 60 Gy	0

received [¹²⁵I] seed brachytherapy postoperatively.

Treatment planning

The brachytherapy treatment planning system (BTPS; Beijing Atom and High Technique Industries, Beijing, China) was used to develop the [¹²⁵I] brachytherapy plan. The planning target volume was defined at 10–15 mm beyond the preoperative gross tumor volume and the postoperative bed from computerized tomogra-

Table 2 Facial nerve function before and after treatment evaluated using the House–Brackman grading system

Time point	Grade				
	I	II	III	IV	V
Before surgery	23				
Before brachytherapy	7	2	7	2	5
Six months after brachytherapy	17	3	2	1	

phy (CT) scans in combination with target area, as recorded by intraoperative photographs. The matched peripheral dose (MPD) was 100–120 Gy for patients without a history of radiotherapy and 80–100 Gy for patients who had previously received radiotherapy. Dosages delivered to organs at risk were designed within acceptable limits of tolerance. A CT scan and BTPS for each patient were obtained immediately after seed implantation to detect seed location and dose distribution.

[¹²⁵I] seed implantation

Implantation of [¹²⁵I] seeds (Model 6711; Beijing Atom and High Technique Industries; $t_{1/2}$, 59.4 days; energy level, 27.4–31.4 KeV) was performed approximately 3–41 days (median, 14 days) postoperatively in all patients after wound healing had been achieved. Activity of the seeds was 25.9–29.6 MBq (0.7–0.8 mCi), and their distribution was determined from CT scans in combination with the target area, as recorded by intraoperative photographs. Hollow interstitial needles (length, 4.5 mm; diameter, 0.8 mm) were inserted 1 cm apart into the target area, which was bound by a 0.5-cm margin. An applicator was then sequentially attached to the distal end of the needles to place the [¹²⁵I] seeds into the target area. The dose distribution involved adjusting the available seed activities and seed positions if necessary. Seeds were placed in the target volume following the implantation plan.

Follow-up

During follow-up, tumor recurrence was monitored by CT scans performed every 2 months, or earlier if a new clinical sign or symptom appeared. The BTPS was

used to analyze the dose at the target area and calculate the remaining dose. Chest X-rays were taken every 6 months following surgery to monitor lung metastasis. Local control (LC) was defined as the lack of tumor progression either within or adjacent to the implanted volume on physical and radiographic examinations.

Facial nerve function was evaluated for each patient prior to brachytherapy and every 6 months postoperatively, according to the House–Brackman (H-B) system (Table 2).

Radiotherapy-associated complications were recorded and graded according to the Radiation Therapy Oncology Group (RTOG) grading system and the National Cancer Institute common toxicity criteria (version 3.0).

Statistical analysis

SPSS 13.0 for Windows (SPSS Inc., Chicago, Ill., USA) was used for data analysis. The Kaplan–Meier test was used to assess overall survival (OS), disease-free survival (DFS), LC and freedom from distant metastasis (FFM). Follow-up data were obtained until February 2014. Recurrence history, local recurrence, distant metastasis, pathology grade, and interval between the operation and brachytherapy were evaluated for their impact on OS by univariate analyses using the classic log-rank test. The impact of recurrence history, pathology grade, interval between the operation and brachytherapy, facial nerve conservation, residual tumor, tumor spillage, and tumor stage on LC were also analyzed.

The Wilcoxon signed-rank test was used to evaluate facial nerve function before and after brachytherapy. In the two-sided test, $p < 0.05$ was considered significant.

Results

Overall and disease-free survival rates

Patients were followed up between 14 and 122 months (median, 58.2 months). The 3-, 5-, and 10-year OS rates were 96.6, 92, and 92 %, respectively, for all patients with a median survival time of 56 months (95 %

M.-H. Mao · J.-G. Zhang · J. Zhang · L. Zheng · S.-M. Liu · M.-W. Huang · Y. Shi

Postoperative [¹²⁵I] seed brachytherapy in the treatment of acinic cell carcinoma of the parotid gland. With associated risk factors

Abstract

Background. This retrospective study was undertaken to analyze data from patients receiving iodine-125 (¹²⁵I) seed brachytherapy postoperatively for the treatment of acinic cell carcinoma (ACC) of the parotid gland along with the following risk factors: residual tumor, recurrent tumor, facial nerve invasion, positive resection margins, advanced tumor stage, or tumor spillage.

Patients and methods. Twenty-nine patients with ACC (17 females, 12 males; age range, 13–73 years; median age, 37.3 years) were included. Median follow-up was 58.2 months (range, 14–122 months). Patients received [¹²⁵I] seed brachytherapy (median ac-

tual D90, 177 Gy) 3–41 days (median, 14 days) following surgery. Radioactivity was 18.5–33.3 MBq per seed, and the prescription dose was 80–120 Gy.

Results. The 3-, 5-, and 10-year rates of local control were 93.1, 88.7, and 88.7%, respectively; overall survival was 96.6, 92, and 92%; disease-free survival was 93.1, 88.4, and 88.4%; and freedom from distant metastasis was 96.6, 91.2, and 91.2%. Lymph node metastases were absent in all patients, although two patients died with distant metastases. Facial nerve recovery was quick, and no severe radiotherapy-related complications were noted. Recurrence history, local recurrence,

and distant metastasis significantly affected overall survival.

Conclusion. Postoperative [¹²⁵I] seed brachytherapy is effective in treating ACC and has minor complications. Patients with a history of recurrence showed poor prognosis and were more likely to experience disease recurrence and develop metastases.

Keywords

[¹²⁵I] seed brachytherapy · Parotid gland · Acinic cell carcinoma · Recurrence · Facial nerve

Postoperative Brachytherapie mit [¹²⁵I]-Seeds bei der Behandlung von Azinuszellkarzinomen der Ohrspeicheldrüse. Mit assoziierten Risikofaktoren

Zusammenfassung

Hintergrund und Ziel. Diese retrospektive Studie wurde durchgeführt, um die Daten von Patienten zu analysieren, die postoperativ eine Seed-Brachytherapie mit Iod-125 (¹²⁵I) zur Behandlung von Azinuszellkarzinomen der Ohrspeicheldrüse mit begleitenden Risikofaktoren, wie Residualtumor, Rezidivtumor, Invasion in den N. facialis, positive (= nicht tumorfreie) Resektionsränder, fortgeschrittenes Tumorstadium oder lokale Verbreitung von Tumorzellen während der Resektion aufwiesen.

Patienten und Methoden. In die Studie wurden 29 Patienten mit Azinuszellkarzinom der Ohrspeicheldrüse (17 weiblich, 12 männlich; Altersbereich 13–73 Jahre; medianes Alter 37,3 Jahre) eingeschlossen. Die media-

ne Nachbeobachtungszeit betrug 58,2 Monate (Spanne 14–122 Monate). Die Patienten erhielten eine [¹²⁵I]-Seed-Brachytherapie an den Tagen 3–41 (Median 14 Tage) nach der Operation. Die Radioaktivität betrug 18,5–33,3 MBq/Seed, die Dosis lag bei 80–120 Gy.

Ergebnisse. Die lokalen 3-, 5- und 10-Jahres-Kontrollraten lagen jeweils bei 93,1, 88,7 und 88,7 %. Absolute Überlebensrate: 96,6, 92 und 92 %. Krankheitsfreie Überlebensrate: 93,1, 88,4 und 88,4 %. Ohne Fernmetastasierung: 96,6, 91,2 und 91,2 %. Lymphknotenmetastasen traten bei keinem Patienten auf, wogegen 2 Patienten mit Fernmetastasen starben. Die Erholung des N. facialis war schnell und es wurden keine ernsthaften, mit der Radiotherapie in Zusammenhang stehen-

den Komplikationen bemerkt. Lagen bereits vorher Rezidive, Lokalrezidive oder Fernmetastasen vor, so beeinflusste dies signifikant die absolute Überlebensrate. Schlussfolgerung. Die Brachytherapie mit [¹²⁵I]-Seeds ist eine effektive Behandlung der Azinuszellkarzinome der Ohrspeicheldrüse mit geringer Komplikationsrate. Patienten, die in der Vergangenheit schon ein Rezidiv gehabt hatten, hatten eine schlechte Prognose und entwickelten mit größerer Wahrscheinlichkeit erneut oder zum ersten Mal Metastasen.

Schlüsselwörter

[¹²⁵I]-Seed-Brachytherapie · Ohrspeicheldrüse · Azinuszellkarzinom · Rezidiv · Nervus facialis

CI, 49.74–62.3 months; ■ Fig. 1). The 3-, 5-, and 10-year DFS rates were 93.1, 88.4, and 88.4 %, respectively, with a median DFS time of 54 months (95 % CI, 46.0–62.0 months; ■ Fig. 2). Local recurrence ($p=0.167$) appeared to have an effect on survival, although it did not reach the significance level, while recurrence history, distant metastasis, pathology grade, and interval between operation and brachytherapy clearly did not.

Two patients died with extensive local disease progression and distant metastases

of the brain, liver, lung, and skin at 14 months and 42 months, respectively, following brachytherapy. Each of these patients had recurrence twice before.

Local control rate

The 3-, 5-, and 10-year LC rates were 93.1, 88.7, and 88.7 %, respectively, with a median LC time of 54 months (95 % CI, 46.0–62.0 months; ■ Fig. 3). The rate of local recurrence was 10.3 %. Three patients experienced recurrence three times

between 6 months and 40 months (mean, 19.3 months) following brachytherapy. Two patients died and one lived for 9 years without recurrence.

Tumor spillage ($p=0.787$), residual tumor ($p=0.320$), facial nerve conservation ($p=0.328$), interval between operation, brachytherapy ($p=0.08$) and pathology grade ($p=0.873$) did not have a significant influence on the LC rate. No locoregional recurrence was found in the initial patient group.

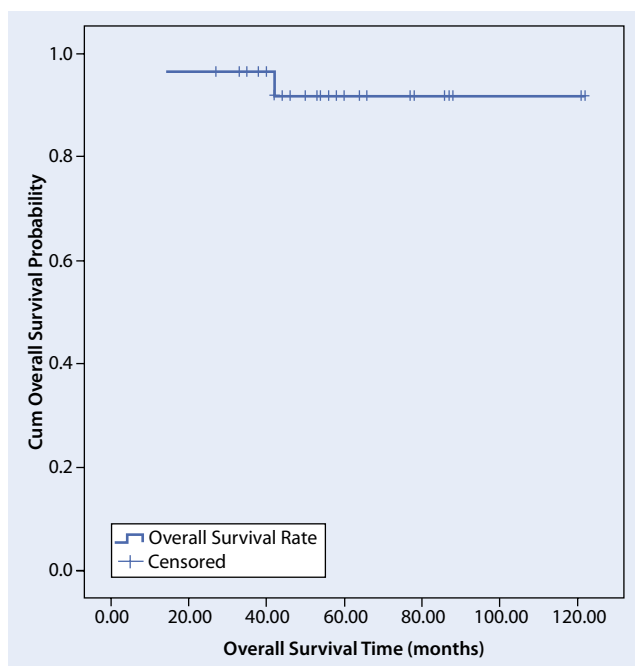


Fig. 1 Overall survival rate

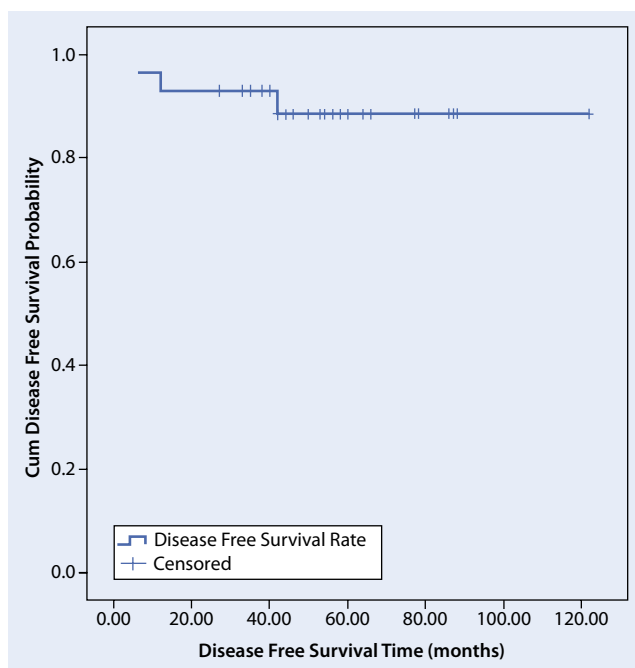


Fig. 2 Disease-free survival rate

Cervical lymph node involvement and distant metastasis

No patients developed cervical lymph node metastasis during the follow-up period.

The 3-, 5-, and 10-year FFM rates were 96.6, 91.2, and 91.2%, respectively, with a median time of 56 months (95% CI, 49.7–62.3 months; **Fig. 4**). Distant me-

tastasis occurred in two patients 12 and 40 months, respectively, after treatment. One patient died of brain metastasis, while the other died of liver, lung, and skin metastases combined with local failure. Both patients had recurrence twice prior to brachytherapy. Compared with primary tumors, recurrent cases may have a higher risk of distant metastasis ($p=0.002$).

Complications

Nearly all patients experienced temporary, minor side effects (RTOG grades 1 and 2) during the treatment, including mild pain, dermatitis, hearing loss, and limited mouth opening without xerostomia. These symptoms lasted 0.5–6 months and resolved without treatment. One patient had limited mouth opening 2 months after treatment but recovered to normal function following 4 months of mouth-opening exercises. Another patient had mild hearing loss without progression. No severe late complications were noted during follow-up, even in patients with previous EBRT.

Facial nerve function

As shown in **Table 2**, facial nerve paralysis was not observed prior to surgical treatment, but was present following brachytherapy. Most patients recovered fully within 6 months of seed implantation ($p<0.001$).

Discussion

ACC of the major salivary glands often occurs in the parotid gland. Most reported cases of parotid gland ACC present with a slowly enlarging, movable, hard mass. However, the incidence of pain and facial nerve palsy is seldom reported, and evidence of lymph node or distant metastasis is rare during the first clinical visit.

In this study, 28 patients had an involved parotid gland and one had an involved infratemporal fossa. The median age of patients was 37.3 years (range, 13–73 years), and the female to male ratio was 1.42:1. At the first visit, no patients had developed a painful mass, experienced facial paralysis, or had metastases to the cervical lymph nodes. These clinical characteristics therefore fall in line with the current general consensus for ACC patients.

Management

Surgical management of ACC is the first line of treatment for resectable cases. For parotid gland cases, excising the tumor by partial parotidectomy is advocated

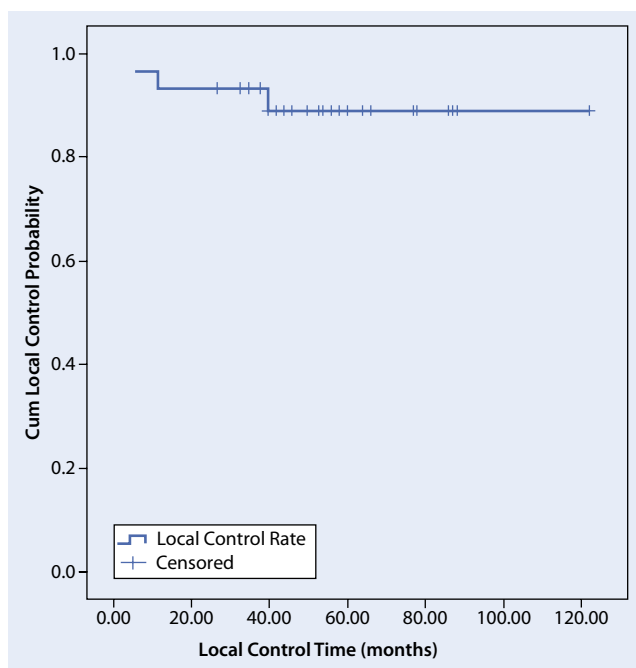


Fig. 3 Local control rate

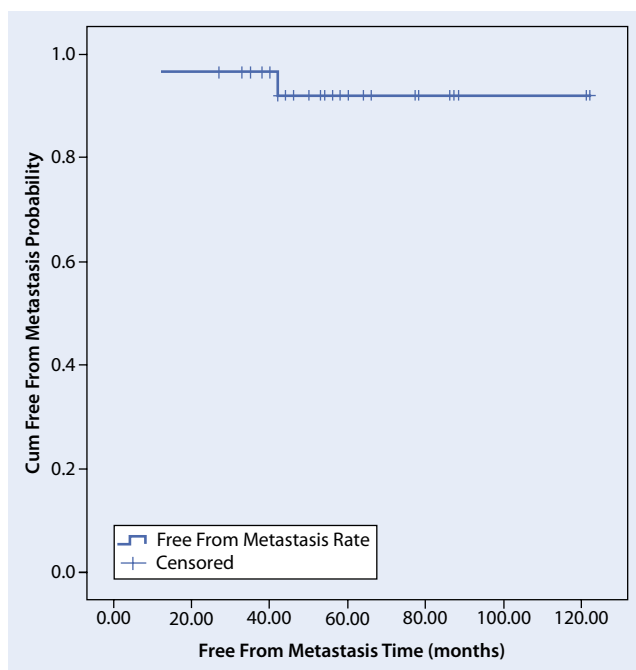


Fig. 4 Freedom from metastasis rate

while preserving the facial nerve. However, the tumor capsule is often adjacent to the nerve, especially in patients with advanced T stage disease, making it difficult to resect. Capsular dissection may therefore be required in this area. This situation is associated with a high recurrence rate [12]. In this study, the facial nerve was sacrificed in the one patient with facial nerve trunk involvement, while being carefully separated from the surround-

ing tissue and tumor mass in 16 other patients. At the follow-up, LC was 88.7% (10 year), and facial nerve function had improved ($p < 0.001$).

The role of elective neck dissection in ACC remains controversial. Neck dissection is not indicated except for patients with clinically obvious cervical nodal involvement [13].

Radiotherapy is not favored as a primary mode of treatment for ACC, as ACC

has generally not been regarded as being very radiosensitive. Nevertheless, there appears to be a role for adjuvant postoperative radiotherapy, although it is poorly defined and controversial [14]. In a study of 1,241 cases of parotid ACC, Andreoli et al. concluded that adjuvant radiotherapy provided no significant overall survival advantage for patients with low-grade, early-stage tumors with complete resection. However, it is unclear whether there would be a benefit for patients with higher grade or higher stage tumors, since too few patients met these criteria in the study. In fact, many authors have claimed a response to postoperative radiotherapy in these patients. Zbären et al. [15] studied the treatment of 98 parotid ACC patients and proposed that postoperative radiotherapy should be given for all high-grade parotid tumors and low-grade tumors that are T2 and higher in staging. North et al. [5] concluded that postoperative radiotherapy is recommended for all cases of salivary gland cancer, not just ACC, except for those tumors staged as T1N0 or T2N0 with low-grade histology, which were excised with negative margins. Spafford et al. [4] proposed a series of indications for postoperative adjunctive radiotherapy in ACC: presence of (a) recurrent tumor; (bi) equivocal positive margins or evidence of tumor spillage; (c) tumor adjacent to the facial nerve; (d) deep-lobe involvement; (e) lymph node metastases; (f) extraparotid extension; and (g) large tumors greater than 4 cm. This suggestion has been generally accepted by most clinicians.

External radiotherapy can enhance LC, but it may have severe complications, such as xerostomia, difficulty in opening the mouth, osteoradionecrosis, and arterial hemorrhage [6–8, 16]. For patients with recurrent tumors after external radiation therapy, the re-delivery of curative doses of external radiation is difficult because of the limited tolerance of normal critical structures. Fast neutron radiotherapy has good efficacy for the treatment of some residual tumors, but its disadvantages are high cost, lack of availability for most hospitals, and grade 3/4 side effects [10].

Brachytherapy addresses many of these problems by delivering a high dose of radiation directly to the tumor and by

Table 3 Overall survival and disease-free survival rates reported in other studies

Study reference	Number of cases	Research style	5-year (%)		10-year (%)	
			OS	DFS	OS	DFS
Bhattacharyya and Fried [30]	95	Retrospective	80		77.7	
Lewis et al. [31]	90	Retrospective	90		83	
Kim et al. [32]	33	Retrospective	95.2	91.6		
Guimaraes et al. [33]	16	Retrospective	66.6		36.4	
Cha et al. [13]	20	Retrospective			90.9	74.2
Gomez et al. [34]	35	Retrospective	90	85		
Spiro et al. [35]	64	Retrospective	76		63	
Perzin and LiVolsi [36]	51	retrospective	78		63	
Lin et al. [37]	25	Retrospective			84	84
Timon et al. [38]	45	Retrospective	81	69		

OS overall survival rate, DFS disease-free survival rate

minimizing nontargeted dose dispersal to the adjacent normal structures. Postoperative [¹²⁵I] brachytherapy is increasingly being found effective for patients with malignant head and neck tumors and in improving LC and patient survival [16–23]. Goffinet et al. [22] reported a 70 % LC rate for patients with recurrent or advanced head and neck cancer who underwent surgery with permanent [¹²⁵I] implant. Glaser et al. [18] reported 2- and 5-year DFS rates of 89 and 53 %, respectively, for cases of recurrent head and neck cancers with postoperative [¹²⁵I] seed brachytherapy and noted that [¹²⁵I] implantation did not lead to complications. Zhang et al. [24] reported a 100 % LC rate and no complications (median follow-up, 66 months; range, 50–74 months) for patients with postoperative residual parotid malignant tumors who received [¹²⁵I] brachytherapy alone. Invaded facial nerves were also conserved and showed good restoration during the follow-up period. Some case reports also showed good results with brachytherapy with different applicators for malignant tumors of the head and neck.

Previous studies compared patients who received surgery alone with those who received surgery and radiotherapy. In this study, all of the 29 patients displayed risk factors and all received surgery and brachytherapy. A treatment strategy was designed based on the medical information, the wishes of the patients, and the presence risk factors. The 3-, 5-, and 10-year OS rates were 96.6, 92, and 92 %, respectively—better than previously reported results (■ Table 3).

Recurrence and metastasis

ACC has a significant tendency to recur and to produce metastases. An average recurrence rate taken from several studies is around 35 % [25–27]. The most common sites of metastasis are cervical lymph nodes (16 % of ACC patients) and the lungs [23–26, 28], and metastases tend to be hematogenous rather than lymphatic.

In this study, three patients had recurrence three times 6–40 months (mean, 19.3 months) after treatment, for an incidence rate of 10.3 %, which is lower than previous reports [25–27]. Patients with recurrence history were more likely to have recurrence again and have a poor prognosis.

Facial nerve function and radiation side effect

In this study, facial nerve function recovered within 6 months of brachytherapy ($p < 0.001$), as previously reported [24]. Like other studies [24, 29], only mild toxicities were observed, such as pain and dermatitis. Severe complications, such as xerostomia and osteoradionecrosis, common with other radiotherapies, were not observed.

Conclusion

Surgery combined with [¹²⁵I] seed brachytherapy is effective in the treatment of parotid ACC that carries risk factors such as residual tumor, recurrent tumor, preservation of invaded facial nerve, positive resection margins, ad-

vanced tumor stage, or tumor spillage. No severe radiotherapy-associated complications were found during the follow-up period. Facial nerve conservation is advised even in patients with advanced T stage or residual tumor, without decreasing the overall survival or lowering the patient's quality of life. Recurrence history, local recurrence, and distant metastasis significantly affected survival. Neck dissection is not proposed for patients without suspected lymph node metastasis.

Corresponding address

Dr. J.-G. Zhang B.S. Med

Department of Oral and Maxillofacial Surgery
Peking University School and Hospital of
Stomatology, 100081 Beijing
rszhang@126.com

Compliance with ethical guidelines

Conflict of interest. M.-H. Mao, J.-G. Zhang, J. Zhang, L. Zheng, S.-M. Liu, M.-W. Huang, and Y. Shi state that there are no conflicts of interest. All studies on humans described in the present manuscript were carried out with the approval of the responsible ethics committee and in accordance with national law and the Helsinki Declaration of 1975 (in its current, revised form). Informed consent was obtained from all patients included in studies.

References

- Godwin JT, Foote FW Jr, Frazell EL (1954) Acinic cell adenocarcinoma of the parotid gland; report of twenty-seven cases. *Am J Pathol* 30:465–477
- Harish K (2004) Management of primary malignant epithelial parotid tumors. *Surg Oncol* 13:7–16
- Stafford ND, Wilde A (1997) Parotid cancer. *Surg Oncol* 6:209–213
- Spafford PD, Mintz DR, Hay J (1991) Acinic cell carcinoma of the salivary gland: review and management. *J Otolaryngol* 20:262–266
- North CA, Lee DJ, Piantadosi S et al (1990) Carcinoma of the major salivary glands treated by surgery or surgery plus postoperative radiotherapy. *Int J Radiat Oncol Biol Phys* 18:1319–1326
- Bhide SA, Harrington KJ, Nutting CM (2007) Otolaryngological toxicity after postoperative radiotherapy for parotid tumors. *Clin Oncol (R Coll Radiol)* 19:77–82
- Li Y, Taylor JMG, Ten Haken RK et al (2007) The impact of dose on parotid salivary recovery in head and neck cancer patients treated with radiation therapy. *Int J Radiat Oncol Biol Phys* 67:660–669
- Notani K, Yamazaki Y, Kitada H et al (2003) Management of mandibular osteoradionecrosis corresponding to the severity of osteoradionecrosis and the method of radiotherapy. *Head Neck* 25:181–186

9. Tribius S, Sommer J, Prosch C et al (2013) Xerostomia after radiotherapy. *Strahlenther Onkol* 189:216–222
10. Douglas JG, Koh WJ, Austin-Seymour M et al (2003) Treatment of salivary gland neoplasms with fast neutron radiotherapy. *Arch Otolaryngol Head Neck Surg* 129:944–948
11. Puthawala A, Nisar Syed A M, Gamie S et al (2001) Interstitial low-dose-rate brachytherapy as a salvage treatment for recurrent head-and-neck cancers: long-term results. *Int J Radiat Oncol Biol Phys* 51:354–362
12. Bron LP, O'Brien CJ (1997) Facial nerve function after parotidectomy. *Arch Otolaryngol Head Neck Surg* 123:1091–1096
13. Cha W, Kim MS, Ahn JC et al (2011) Clinical analysis of acinic cell carcinoma in parotid gland. *Clin Exp Otorhinolaryngol* 4:188–192
14. Andreoli MT, Andreoli SM, Shrimme MG et al (2012) Radiotherapy in parotid acinic cell carcinoma: does it have an impact on survival? *Arch Otolaryngol Head Neck Surg* 138:436–436
15. Zbären P, Schüpbach J, Nuyens M et al (2003) Carcinoma of the parotid gland. *Am J Surg* 186:57–62
16. Connor NP, Cohen SB, Kammer RE et al (2006) Impact of conventional radiotherapy on health-related quality of life and critical functions of the head and neck. *Int J Radiat Oncol Biol Phys* 65:1051–1062
17. Jiang YL, Meng N, Wang JJ et al (2010) CT-guided iodine-125 seed permanent implantation for recurrent head and neck cancers. *Radiat Oncol* 5:68
18. Glaser MG, Leslie MD, Coles I et al (1995) Iodine seeds in the treatment of slowly proliferating tumors in the head and neck region. *Clin Oncol (R Coll Radiol)* 7:106–109
19. Vikram B, Hilaris BS, Anderson L et al (1983) Permanent iodine-125 implants in head and neck cancer. *Cancer* 51:1310–1314
20. Jen-Lee D, Liberman FZ, Park RI et al (1991) Intraoperative I-125 seed implantation for extensive recurrent head and neck carcinomas. *Radiology* 178:879–882
21. Stannard CE, Hering E, Hough J et al (2004) Post-operative treatment of malignant salivary gland tumors of the palate with iodine-125 brachytherapy. *Radiother Oncol* 73:307–311
22. Goffinet DR, Martinez A, Fee WE Jr (1985) 125 I vicryl suture implants as a surgical adjuvant in cancer of head and neck. *Int J Radiat Oncol Biol Phys* 11:399–402
23. Huang MW, Zheng L, Liu SM et al (2013) 125I brachytherapy alone for recurrent or locally advanced adenoid cystic carcinoma of the oral and maxillofacial region. *Strahlenther Onkol* 189:502–507
24. Zhang J, Zhang JG, Song TL et al (2008) 125 I seed implant brachytherapy-assisted surgery with preservation of the facial nerve for treatment of malignant parotid gland tumors. *Int J Oral Maxillofac Surg* 37:515–520
25. Hoffman HT, Karnell LH, Robinson RA et al (1999) National Cancer Data Base report on cancer of the head and neck: acinic cell carcinoma. *Head Neck* 21:297–309
26. Barnes L, Eveson JW, Reichart P, Sidransky D (Eds) (2005) World Health Organization classification of tumours: pathology and genetics of head and neck tumours. IARC Press, Lyon
27. Stewart AK, Bland KI, McGinnis LS et al (2000) Clinical highlights from the National Cancer Data Base. *CA Cancer J Clin* 50:171–183
28. Nakamura H, Miyasaka S, Kanaoka Y et al (1994) A case of metastatic lung tumor from acinic cell tumor of the parotid gland. *Nippon Kyobu Geka Gakkai Zasshi*. 42:1960–1962
29. Zheng L, Zhang J, Song T et al (2013) 125I seed implant brachytherapy for the treatment of parotid gland cancers in children and adolescents. *Strahlenther Onkol* 189:401–406
30. Bhattacharyya N, Fried MP (2005) Determinants of survival in parotid gland carcinoma: a population-based study. *Am J Otolaryngol* 26:39–44
31. Lewis JE, Olsen KD, Weiland LH (1991) Acinic cell carcinoma. Clinicopathologic review. *Cancer* 67:172–179
32. Kim JW, Lim YC, Hong HJ (2009) P1.07. Acinic cell carcinoma of the parotid gland. *Oral Oncol Suppl* 3:125
33. Guimaraes DS, Amaral AP, Prado LF et al (1989) Acinic cell carcinoma of salivary glands: 16 cases with clinicopathologic correlation. *J Oral Pathol Med* 18:396–399
34. Gomez DR, Katabi N, Zhung J et al. (2009) Clinical and pathologic prognostic features in acinic cell carcinoma of the parotid gland. *Cancer* 115:2128–2137
35. Spiro RH, Huvos AG, Strong EW (1978) Acinic cell carcinoma of salivary origin. A clinicopathologic study of 67 cases. *Cancer* 41:924–935
36. Perzin KH, Livolsi VA (1979) Acinic cell carcinomas arising in salivary glands: a clinicopathologic study. *Cancer* 44:1434–1457
37. Lin WN, Huang HC, Wu CC et al (2010) Analysis of acinic cell carcinoma of the parotid gland—15 years experience. *Acta Otolaryngol* 130:1406–1410
38. Timon CI, Dardick I, Panzarella T et al (1994) Acinic cell carcinoma of salivary glands. Prognostic relevance of DNA flow cytometry and nucleolar organizer regions. *Arch Otolaryngol Head Neck Surg* 120:727–733